

Bifid Mandibular Canal in Japanese

Munetaka Naitoh, DDS, PhD,* Yuichiro Hiraiwa, DDS,† Hidetoshi Aimiya, DDS,† Masakazu Gotoh, DDS,‡ Yoshiko Arijii, DDS, PhD,§ Masahiro Izumi, DDS, PhD,|| Kenichi Kurita, DDS, PhD,¶ and Eiichiro Arijii, DDS, PhD**

The mandibular canal passes the interior mandibular from the mandibular foramen to the mental foramen, involving the inferior alveolar artery and inferior alveolar nerve. The location and configuration of mandibular canal variations are important in surgical procedures involving the mandible, such as extraction of an impacted third molar, dental implant treatment, and sagittal split ramus osteotomy.

Some variations of the mandibular canal (so-called bifid mandibular) have been reported from North America, Europe, and Africa.¹⁻¹¹ When we reviewed the literature regarding bifid mandibular canal using the PubMed database (National Library of Medicine, Bethesda, MD), we could find no reports from Asia.

Here, we report 3 Japanese patients with bifid mandibular canal/canals using panoramic radiograph and multi-slice helical computed tomography (CT).

MATERIALS AND METHODS

Panoramic Radiography

A panoramic machine, Veraview Epocs (Morita Co., Kyoto, Japan), was

The location and configuration of mandibular canal variations are important in surgical procedures involving the mandible, such as extraction of an impacted third molar, dental implant treatment, and sagittal split ramus osteotomy. We report 3 Japanese patients with bifid mandibular canals using panoramic radiograph and multi-slice helical computed tomography (CT) images. In 2 of the 5 sides, the bifid mandibular canal was suggested on panoramic radiograph. The bifid mandibular canal had a short and narrow upper canal toward the

distal area of the second molar in 4 sides, and a short and narrow lower canal toward the distal area of second molar in 1 side, as revealed on reconstructed CT images. Since the location and configuration of mandibular canal variations are important in surgical procedures involving the mandible, they should be carefully observed using reconstructed CT images. (Implant Dent 2007;16:24-32)

Key Words: mandibular canal, bifurcation, computed tomography, dental implant

used. Panoramic images were processed using the CR system (Regius 190; Konica Minolta, Tokyo, Japan) and linear gradation process.

Multi-Slice Helical CT

A multi-slice helical CT unit, HiSpeed NX/i Pro (GE Yokogawa Medical Systems, Tokyo, Japan), was used, and the helical scans were set at 1.0-mm thick slices with a 1.5-table pitch. The axial images were produced with 1.0-mm thick slices at 1.0-mm intervals, and then the 2-dimensional (2-D) images of various planes were reconstructed using a double-oblique program.

CASE REPORTS

Patient 1: Male, 46 Years Old

Panoramic radiography and multi-slice helical CT were taken for detailed examination in the left mandibular third molar region. On the panoramic image (Fig. 1A), the left bifid mandibular canal was suggested, however, the right bifid mandibular canal did not appear.

In addition, on the reconstructed CT images (Figs. 1B and C), the man-

dibular canal in both sides was raised from each single mandibular foramen and then immediately bifurcated. Each lower canal in both sides coursed toward each mental foramen. The left upper canal, which was slightly narrow compared with the lower canal, coursed toward the distal area of the second molar and the point extended to the lingual side. The right narrow upper canal coursed toward the distal area of the second molar.

Patient 2: Female, 38 Years Old

Panoramic radiography and multi-slice helical CT were taken for detailed examination in the right mandibular second molar and surrounding region. On the panoramic image (Fig. 2A), the left bifid mandibular canal was suggested, and the right mandibular canal was slightly expanded in the root apex of the third molar. On the reconstructed CT images (Figs. 2B and C), the mandibular canal in both sides was raised from each single mandibular foramen and bifurcated in the third molar. Each lower canal in both sides coursed toward each mental foramen.

*Associate Professor, Department of Oral and Maxillofacial Radiology, School of Dentistry, Aichi-Gakuin University; Chief of Oral Implant Clinic, Dental Hospital, Aichi-Gakuin University, Nagoya, Japan.

†Part-time Instructor, Department of Oral and Maxillofacial Radiology, School of Dentistry, Aichi-Gakuin University, Nagoya, Japan.

‡Instructor, Department of Oral and Maxillofacial Radiology, School of Dentistry, Aichi-Gakuin University, Nagoya, Japan.

§Assistant Professor, Department of Oral and Maxillofacial Radiology, School of Dentistry, Aichi-Gakuin University, Nagoya, Japan.

||Associate Professor, Department of Oral and Maxillofacial Radiology, School of Dentistry, Aichi-Gakuin University, Nagoya, Japan.

¶Professor and Chairman, The first department of Oral and Maxillofacial Surgery, School of Dentistry, Aichi-Gakuin University, Nagoya, Japan.

**Professor and Chairman, Department of Oral and Maxillofacial Radiology, School of Dentistry, Aichi-Gakuin University, Nagoya, Japan.

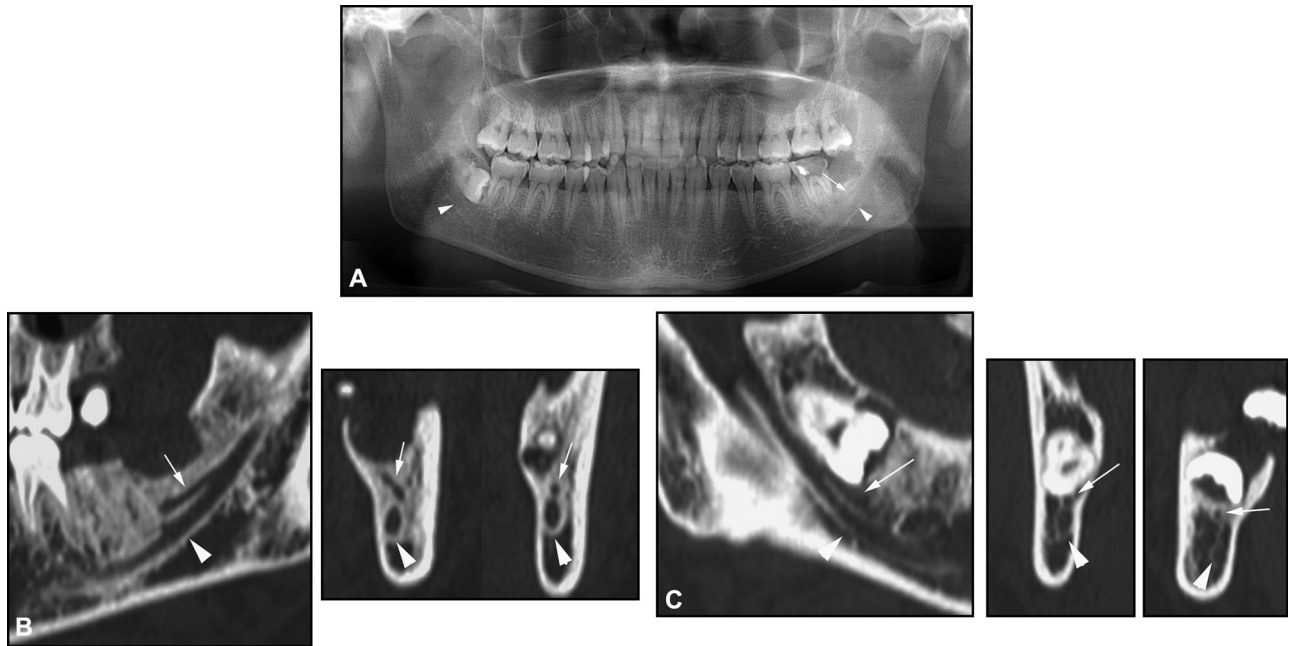


Fig. 1. Radiographs of patient 1. A, Panoramic image. B, Reconstructed CT image in the left side. C, Reconstructed CT image in right side. The left bifid mandibular canal was suggested on the panoramic image. In the left mandible, there was a single mandibular foramen, and the upper canal narrowed toward the distal area of the second molar after the bifurcation on the reconstructed CT images. In addition, in the right mandible, there was a single mandibular foramen, and the upper canal narrowed along the third molar after the bifurcation on the reconstructed CT images.

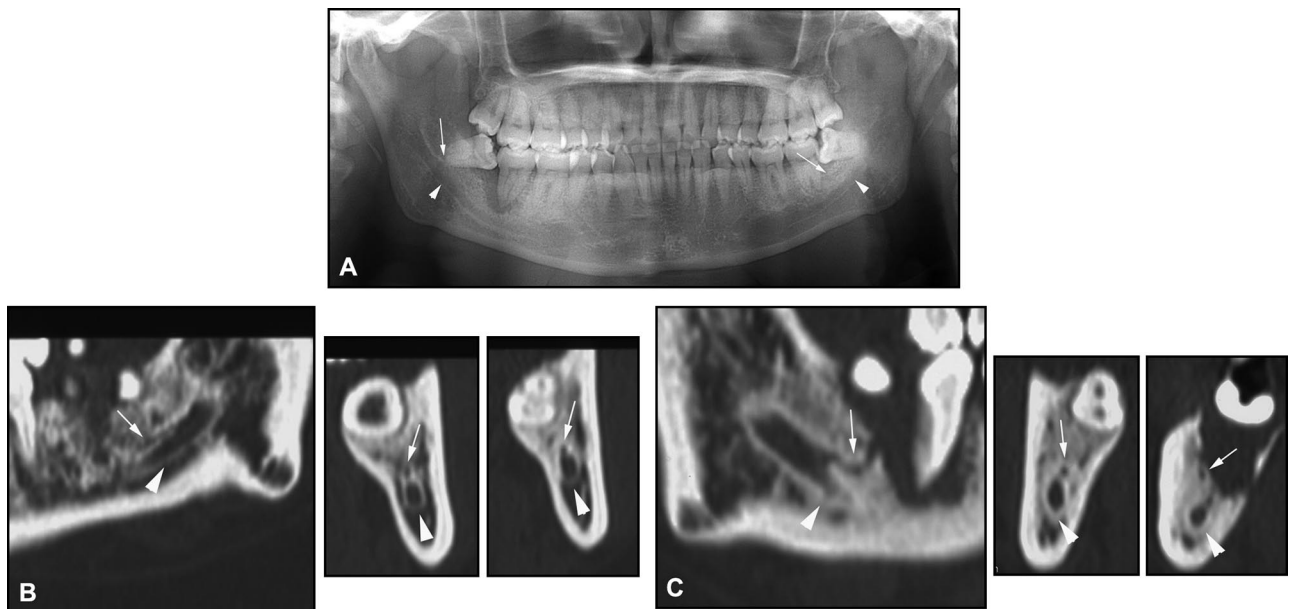


Fig. 2. Radiographs of patient 2. A, Panoramic image. B, Reconstructed CT images in left side. C, Reconstructed CT images in right side. The left bifid mandibular canal was suggested, and the right mandibular canal slightly expanded in the root apex of the third molar on the panoramic image. In the left mandible, there was a single mandibular foramen and bifurcation of the mandibular canal in the third molar on the reconstructed CT images. The upper canal ran along the mandibular canal. In the right mandible, there was a single mandibular foramen and bifurcation of the mandibular canal in the third molar on the reconstructed CT images.

The left narrow upper canal coursed toward the distal area of the second molar. The right narrow upper canal coursed toward the distal area of the second molar and the point extended to the buccal side.

Patient 3: Female, 31 Years Old

Panoramic radiography and multi-slice helical CT were taken for detailed examination in the left mandibular third molar region. On the panoramic image (Fig. 3A), the left bifid mandib-

ular canal did not appear. On the reconstructed CT images (Fig. 3B), the left mandibular canal was raised from the single mandibular foramen and then immediately bifurcated. The upper canal coursed toward a mental foramen.

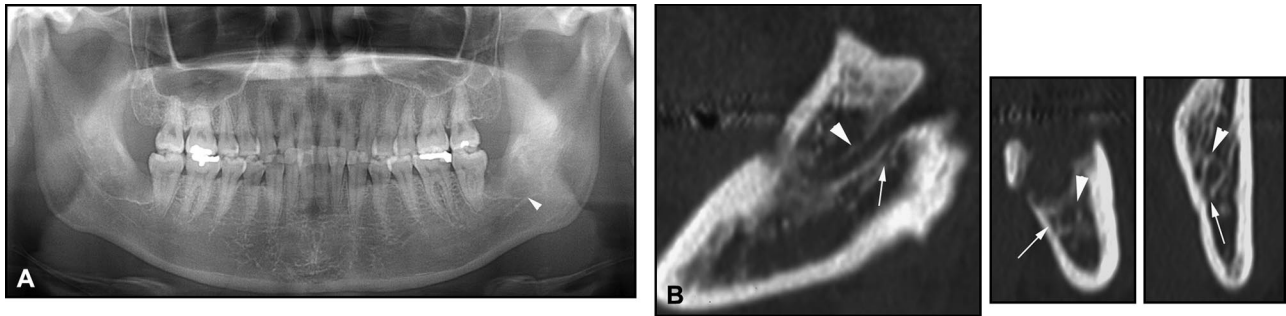


Fig. 3. Radiographs of patient 3. A, Panoramic image. B, Reconstructed CT images in the left side. On the panoramic image, the bifid mandibular canal did not appear. On the reconstructed CT images of the left mandible, there was a single mandibular foramen and narrow lower canal toward the distal area of the second molar after the bifurcation.

The narrow lower canal coursed toward the distal area of the second molar and the point located along the lingual cortical bone.

DISCUSSION

Some reports exist regarding bifid mandibular canals.¹⁻¹¹ Grover and Lorton⁶ reported an incidence of 0.08%, with highly suggestive bifurcation of the inferior alveolar nerves in a panoramic radiographic survey. Also, Sancbis *et al*¹⁰ reported an incidence of 0.35%, suggestive of a double mandibular canal in panoramic radiography. Moreover, Nortje *et al*³ reported that duplication or division of the mandibular canal was found in 0.9% in a review of panoramic radiographs. Langlais *et al*⁷ reported that bifid inferior mandibular canals were seen at a rate of 0.95% in panoramic radiographs. In only 2 of our 5 sides, the bifid mandibular canal was suggested on panoramic image. Three-dimensional (3-D) anatomical structures are projected onto 2-D film in panoramic radiography. Klinge *et al*¹² reported that mandibular canal of specimen cadavers was not visible in 36.1% of panoramic radiographs. Also, Lindhe *et al*¹³ reported that the mandibular canal of specimen cadavers was clearly visible in approximately 25% of panoramic radiographs. Thus, it was considered that there was a limitation in the observation of the mandibular canal using panoramic radiography. Detailed 2-D and 3-D images could be reconstructed using multi-slice helical CT.^{14,15} The narrower bifid mandibular canal in our 3 sides could be observed on the reconstructed CT images of various planes. When further studies

regarding the bifid mandibular canal will be conducted using multi-slice helical CT, a frequency of the bifid mandibular canal will increase compared with previous studies using panoramic radiography.

Two of our 3 patients were bilateral. Langlais *et al*⁷ reported that it was observed in 46 patients unilaterally and 11 patients bilaterally, whereas, Sancbis *et al*¹⁰ reported that it was unilateral in 3 cases and bilateral in 4 cases. Also, Nortje *et al*³ reported that it was present in 13 individuals unilaterally and 20 individuals bilaterally.

The various types of mandibular canals have been classified according to anatomical location and configuration using panoramic radiography.^{3,4,7} Nortje *et al*^{3,4} described 4 main patterns of duplication, and Langlais *et al*⁷ noted 4 main patterns of bifid mandibular canal. The pattern of bifid mandibular canal in 4 (patients 1 and 2) of 5 sides corresponded to type 2 by Nortje *et al*³ and type 2 by Langlais *et al*⁷. Moreover, it was considered that patient 3, with the narrow lower canal, corresponded to type 1 by Nortje *et al*³ and type 2 by Langlais *et al*⁷.

The location and configuration of the mandibular canal should be carefully observed using cross-sectional images of the mandible or mandibular canal and images perpendicular to them, reconstructed by multi-slice helical CT, when conducting surgical procedures involving the mandible.

CONCLUSIONS

We reported 3 Japanese patients with bifid mandibular canal/canals. Since the location and configuration of

mandibular canal variations are important in surgical procedures involving the mandible, they should be carefully observed using cross-sectional and perpendicular images reconstructed by multi-slice helical CT.

Disclosure

The authors claim to have no financial interest in any company or any of the products mentioned in this article.

REFERENCES

1. Kiersh TA, Jordan JE. Duplication of the mandibular canal. *Oral Surg Oral Med Oral Pathol.* 1973;35:133-134.
2. Patterson JE, Funke FW. Bifid inferior alveolar canal. *Oral Surg Oral Med Oral Pathol.* 1973;36:287-288.
3. Nortje CJ, Farman AG, Grotepass FW. Variations in the normal anatomy of the inferior dental (mandibular) canal: A retrospective study of panoramic radiographs from 3612 routine dental patients. *Br J Oral Surg.* 1977;15:55-63.
4. Nortje CJ, Farman AG, De V Joubert JJ. The radiographic appearance of the inferior dental canal: an additional variation. *Br J Oral Surg.* 1977;15:171-172.
5. Mader CL, Kanzelman JL. Branching mandibular canal. *Oral Surg Oral Med Oral Pathol.* 1981;51:332.
6. Grover PS, Lorton L. Bifid mandibular nerve as a possible cause of inadequate anesthesia in the mandible. *J Oral Maxillofac Surg.* 1983;41:177-179.
7. Langlais RP, Broadus R, Glass BJ. Bifid mandibular canals in panoramic radiographs. *J Am Dent Assoc.* 1985;110:923-926.
8. Driscoll CF. Bifid mandibular canal. *Oral Surg Oral Med Oral Pathol.* 1990;70:807.
9. Wyatt WM. Accessory mandibular canal: Literature and presentation of an additional variant. *Quintessence Int.* 1996;27:111-113.
10. Sancbis JM, Penaroba M, Soler F. Bifid mandibular canal. *J Oral Maxillofac Surg.* 2003;61:422-424.

11. Claeys V, Wackens G. Bifid mandibular canal: Literature review and case report. *Dentomaxillofac Radiol.* 2005;34:55-58.

12. Klinge B, Petersson A, Maly P. Location of the mandibular canal: Comparison of macroscopic findings, conventional radiography, and computed tomography. *Int J Oral Maxillofac Implants.* 1989;4:327-332.

13. Lindhe C, Petersson A, Klinge B. Visualization of the mandibular canal by different radiographic techniques. *Clin Oral Implants Res.* 1992;3:90-97.

14. Naitoh M, Katsumata A, Nohara E, et al. Measurement accuracy of reconstructed 2-D images obtained by multislice helical computed tomography. *Clin Oral Implants Res.* 2004;15:570-574.

15. Naitoh M, Katsumata A, Kubota Y, et al. Assessment of three-dimensional X-ray images: Reconstruction from conventional tomograms, compact computerized tomography images, and multislice helical computerized tomography images. *J Oral Implantol.* 2005;31:234-241.

Reprint requests and correspondence to:

Munetaka Naitoh, DDS, PhD
Department of Oral and Maxillofacial Radiology
School of Dentistry
Aichi-Gakuin University
2-11, Suemori-Dori
Chikusa-Ku
Nagoya 464-8651, Japan
Phone: (81) 52759-2165
Fax: (81) 52759-2165
E-mail: mune@dpc.aichi-gakuin.ac.jp



Abstract Translations

GERMAN / DEUTSCH

AUTOR(EN): Munetaka Naitoh, DDS, PhD*, Yuichiro Hiraiwa, DDS**, Hidetoshi Aimiya, DDS***, Masakazu Gotoh, DDS****, Yoshiko Arijii, DDS, PhD#, Masahiro Izumi, DDS, PhD##, Kennichi Kurita, DDS, PhD### und Eiichiro Arijii, DDS, PhD+. *A.O. Professor, Abteilung für Radiologie im Gesichts- und Kieferbereich, Zahnmedizinische Fakultät, Aichi-Gakuin Universität; Leiter der Klinik für orale Implantologie, Zahnheilkundliche Fachklinik, Aichi-Gakuin Universität. **Dozent in Teilzeit, Abteilung für Radiologie im Gesichts- und Kieferbereich, Zahnmedizinische Fakultät, Aichi-Gakuin Universität. ***Dozent in Teilzeit, Abteilung für Radiologie im Gesichts- und Kieferbereich, Zahnmedizinische Fakultät, Aichi-Gakuin Universität. ****Dozent in Teilzeit, Abteilung für Radiologie im Gesichts- und Kieferbereich, Zahnmedizinische Fakultät, Aichi-Gakuin Universität. #Assistenzprofessor, Abteilung für Radiologie im Gesichts- und Kieferbereich, Zahnmedizinische Fakultät, Aichi-Gakuin Universität; ##A.O. Professor, Abteilung für Radiologie im Gesichts- und Kieferbereich, Zahnmedizinische Fakultät, Aichi-Gakuin Universität; ###Professor und Leiter, Erste Abteilung für Radiologie im Gesichts- und Kieferbereich, Zahnmedizinische Fakultät, Aichi-Gakuin Universität; +Professor und Leiter, Abteilung für Radiologie im Gesichts- und Kieferbereich, Zahnmedizinische Fakultät, Aichi-Gakuin Universität; Schriftverkehr: Munetaka Naitoh, DDS, PhD, Abteilung für Radiologie im Gesichts- und Kieferbereich (Dept. of Oral and Maxillofacial Radiology), Zahnmedizinische Fakultät (School of Dentistry), Aichi-Gakuin Universität (Aichi-Gakuin University), 2-11, Suemori-Dori, Chikusa-Ku, Nagoya 464-8651, Japan. eMail: mune@dpc.aichi-gakuin.ac.jp

Zweiteilung des Unterkieferkanals bei Menschen japanischer Abstammung

ZUSAMMENFASSUNG: Lage und Struktur von Variationen des Unterkieferkanals sind bei chirurgischen Eingriffen am Unterkiefer von Bedeutung, so beispielsweise bei der Extraktion eines dritten verlagerten Mahlzahns, bei Zahnimplantationsbehandlungen sowie bei Osteotomie des

sagital gespaltenen Zweiges. Wir berichten über drei japanische Patienten mit zweigeteilten Unterkieferkanälen unter Beistellung von Panoramaröntgenaufnahmen und vielschichtigen, schraubenförmig aufgenommenen Computertomographischen Bildern. Bei zwei der insgesamt 5 Fundstellen wurde die Zweiteilung des Unterkieferkanals durch die Panoramaröntgenaufnahme festgestellt. Der zweigeteilte Unterkieferkanal verfügt über einen kurzen und engen oberen Kanal hin zum distalen Bereich des zweiten Mahlzahns bei vier Stellen und einem kurzen und engen unteren Kanal gegenüber dem distalen Bereich des zweiten Molars bei einer Stelle, wie die Rekonstruktion auf den Computertomographischen Bildern ausweist. Da Lage und Struktur von Variationen des Unterkieferkanals bei chirurgischen Eingriffen am Unterkiefer wichtig sind, sollten diese über rekonstruierte Computertomographieaufnahmen besonders sorgfältig beobachtet und eingeschätzt werden.

SCHLÜSSELWÖRTER: Unterkieferkanal, Bifurkation, Computertomographie, Zahnimplantat

SPANISH / ESPAÑOL

AUTOR(ES): Munetaka Naitoh, DDS, PhD*, Yuichiro Hiraiwa, DDS**, Hidetoshi Aimiya, DDS***, Masakazu Gotoh, DDS****, Yoshiko Arijii, DDS, PhD#, Masahiro Izumi, DDS, PhD##, Kennichi Kurita, DDS, PhD###, y Eiichiro Arijii, DDS, PhD+. *Profesor Asociado, Departamento de Radiología Oral y Maxilofacial, Facultad de Odontología, Universidad Aichi-Gakuin; Jefe de la Clínica de Implantes Orales, Hospital Odontológico, Universidad de Aichi-Gakuin. **Instructor a tiempo parcial, Departamento de Radiología Oral y Maxilofacial, Facultad de Odontología, Universidad Aichi-Gakuin. ***Instructor de a tiempo parcial, Departamento de Radiología Oral y Maxilofacial, Facultad de Odontología, Universidad Aichi-Gakuin. ****Instructor, Departamento de Radiología Oral y Maxilofacial, Facultad de Odontología, Universidad Aichi-Gakuin. #Profesor Asistente, Departamento de Radiología Oral y Maxilofacial, Facultad de Odontología, Universidad Aichi-

Gakuin. ##Profesor Asociado, Departamento de Radiología Oral y Maxilofacial, Facultad de Odontología, Universidad Aichi-Gakuin. ###Profesor y Jefe, El primer departamento de Cirugía Oral y Maxilofacial, Facultad de Odontología, Universidad Aichi-Gakuin. +Profesor y Jefe, Departamento de Radiología Oral y Maxilofacial, Facultad de Odontología, Universidad Aichi-Gakuin. Correspondencia a: Munetaka Naitoh, DDS, PhD, Dept. of Oral and Maxillofacial Radiology, School of Dentistry, Aichi-Gakuin University, 2-11, Suemori-Dori, Chikusa-Ku, Nagoya 464-8651, Japan. Correo electrónico: mune@dpc.aichi-gakuin.ac.jp

Canal mandibular bífido en los japoneses

ABSTRACTO: La ubicación y configuración de las variaciones del canal mandibular son importantes en procedimientos quirúrgicos que incluyen a la mandíbula, tales como la extracción del tercer molar impactado, tratamientos con implantes dentales y osteotomía del ramus sagital dividido. Informamos sobre tres pacientes japoneses con canales mandibulares bífidos usando radiografías panorámicas y múltiples imágenes de tomografías computadas helicoidales. En dos de los cinco costados, se sugirió el canal mandibular bífido en la radiografía panorámica. El canal mandibular bífido tenía un canal superior corto y angosto hacia el área distal del segundo molar en cuatro costados y un canal inferior corto y angosto hacia el área distal del segundo molar en un costado, como lo indicaron las imágenes reconstruidas de las tomografías computadas. Debido a que la ubicación y configuración de las variaciones del canal mandibular son importantes en los procedimientos quirúrgicos que incluyen a la mandíbula, deberían ser observados cuidadosamente usando imágenes reconstruidas de la tomografía computada.

PALABRAS CLAVES: canal mandibular, bifurcación, tomografía computada, implante dental

PORTUGUESE / PORTUGUÊS

AUTOR(ES): Munetaka Naitoh, Cirurgião-Dentista, PhD*, Yuichiro Hiraiwa, Cirurgião-Dentista**, Hidetoshi Aimiya, Cirurgião-Dentista***, Masakazu Gotoh, Cirurgião-Dentista****, Yoshiko Arijii, Cirurgião-Dentista, PhD#, Masahiro Izumi, Cirurgião-Dentista, PhD###, Kennichi Kurita, Cirurgião-Dentista, PhD####, e Eiichiro Arijii, Cirurgião-Dentista, PhD+. *Professor Associado, Departamento de Radiologia Oral e Maxilofacial, Faculdade de Odontologia, Universidade Aichi-Gakuin; Chefe de Clínica de Implantes Orais, Hospital Odontológico, Universidade, Aichi-Gakuin. **Instrutor em Tempo Parcial, Departamento de Radiologia Oral e Maxilofacial, Faculdade de Odontologia, Universidade, Aichi-Gakuin. ***Instrutor em Tempo Parcial, Departamento de Radiologia Oral e Maxilofacial, Faculdade de Odontologia, Universidade, Aichi-Gakuin. ****Instrutor, Departamento de Radiologia Oral e Maxilofacial, Faculdade de Odontologia, Universidade Aichi-Gakuin. #Professor Assistente, Departamento de Radiologia Oral e Maxilofacial, Faculdade de Odontologia, Universidade, Aichi-Gakuin. ##Professor Associado, Departamento de Radiologia Oral e Maxilofacial, Faculdade de

Odontologia, Universidade, Aichi-Gakuin. ###Professor e Presidente do primeiro departamento de Cirurgia Oral e Maxilofacial, Faculdade de Odontologia, Universidade, Aichi-Gakuin. + Professor e Presidente, Departamento de Radiologia Oral e Maxilofacial, Faculdade de Odontologia, Universidade Aichi-Gakuin. Correspondência para: Munetaka Naitoh, DDS, PhD, Dept. of Oral and Maxillofacial Radiology, School of Dentistry, Aichi-Gakuin University, 2-11, Suemori-Dori, Chikusa-Ku, Nagoya 464-8651, Japan. E-Mail: mune@dpc.aichi-gakuin.ac.jp

Canal Bífido Mandibular Canal em Japoneses

RESUMO: O local e configuração de variações do canal mandibular são importantes nos procedimentos cirúrgicos envolvendo a mandíbula, tais como extração de um terceiro molar impactado, tratamento de implante dentário e osteotomia do ramo sagital. Relatamos três pacientes japoneses com canais mandibulares bífidos usando radiografia panorâmica e imagens de CT de hélice múltipla. Em dois dos cinco lados, o canal bífido mandibular foi sugerido na radiografia panorâmica. O canal bífido mandibular tinha um canal superior curto e estreito na direção da área distal do segundo molar em quatro lados e um canal mais baixo curto e estreito na direção da área distal do segundo molar em um lado, como revelado em imagens de CT reconstruídas. Desde que o local e configuração de variações do canal mandibular são importantes em procedimentos cirúrgicos envolvendo a mandíbula, elas devem ser cuidadosamente observadas usando imagens de CT reconstruídas.

PALAVRAS-CHAVE: canal mandibular, bifurcação, tomografia computadorizada, implante dentário

RUSSIAN / РУССКИЙ

АВТОРЫ: Munetaka Naitoh, доктор стоматологии, кандидат наук*, Yuichiro Hiraiwa, доктор стоматологии**, Hidetoshi Aimiya, доктор стоматологии***, Masakazu Gotoh, доктор стоматологии****, Yoshiko Arijii, доктор стоматологии, кандидат наук, #Masahiro Izumi, доктор стоматологии, кандидат наук, ##Kennichi Kurita, доктор стоматологии, кандидат наук###, и Eiichiro Arijii, доктор стоматологии, кандидат наук+. *Доцент, Кафедра челюстно-лицевой рентгенологии и рентгенологии ротовой полости, Факультет стоматологии, Университет Aichi-Gakuin; Руководитель клиники имплантации в ротовой полости, Стоматологическая больница, Университет Aichi-Gakuin. **Преподаватель по совместительству, Кафедра челюстно-лицевой рентгенологии и рентгенологии ротовой полости, Факультет стоматологии, Университет Aichi-Gakuin. ***Преподаватель по совместительству, Кафедра челюстно-лицевой рентгенологии и рентгенологии ротовой полости, Факультет стоматологии, Университет Aichi-Gakuin. ****Преподаватель по совместительству, Кафедра челюстно-лицевой рентгенологии и рентгенологии ротовой полости, Факультет стоматологии, Университет Aichi-Gakuin. #Преподаватель, Кафедра челюстно-лицевой рентгенологии и рентгенологии ротовой полости, Факультет стоматологии, Университет Aichi-Gakuin.

#Доцент, Кафедра челюстно-лицевой рентгенологии и рентгенологии ротовой полости, Факультет стоматологии, Университет Aichi-Gakuin. ##Доцент, Кафедра челюстно-лицевой рентгенологии и рентгенологии ротовой полости, Факультет стоматологии, Университет Aichi-Gakuin. ###Профессор и председатель кафедры, Первая кафедра челюстно-лицевой рентгенологии и рентгенологии ротовой полости, Факультет стоматологии, Университет Aichi-Gakuin. +Профессор и председатель кафедры, Кафедра челюстно-лицевой рентгенологии и рентгенологии ротовой полости, Факультет стоматологии, Университет Aichi-Gakuin. Почтовый адрес: Munetaka Naitoh, DDS, PhD, Dept. of Oral and Maxillofacial Radiology, School of Dentistry, Aichi-Gakuin University, 2-11, Suemori-Dori, Chikusa-Ku, Nagoya 464-8651, Japan. Адрес электронной почты: mune@dpc.aichi-g

Раздвоенный нижнечелюстной канал (на японском языке)

РЕЗЮМЕ: Местоположение и конфигурация разновидностей нижнечелюстного канала важны в хирургических операциях на нижней челюсти, таких как удаление ретинированного третьего моляра, зубная им-

плантация и пломбирование ветви челюсти. Мы предоставляем данные о трех японских пациентах с раздвоенным нижнечелюстным каналом, полученные с помощью панорамной рентгенограммы и снимков спиральной компьютерной томографии.

На двух из пяти сторон раздвоенный нижнечелюстной канал был показан на панорамной рентгенограмме. Раздвоенный нижнечелюстной канал имел один короткий и узкий верхний канал ближе к дистальной зоне второго моляра с четырех сторон и короткий и узкий нижний канал ближе к дистальной зоне второго моляра с одной стороны, что было выявлено на восстановленных снимках компьютерной томографии.

Поскольку местоположение и конфигурация разновидностей нижнечелюстного канала важны в хирургических операциях на нижней челюсти, в отношении их должен проводиться тщательный контроль с помощью восстановленных снимков компьютерной томографии.

КЛЮЧЕВЫЕ СЛОВА: канал нижней челюсти, раздвоенный, компьютерная томография, зубной имплантат

日本人における二分下顎管

著者: ムネカタ・ナイトー, DDS, PhD*, ユウイチロウ・ヒライワ, DDS**, ヒデトシ・アイミヤ, DDS***, マサカズ・ゴトー, DDS****, ヨシコ・アリジ, DDS#, PhD, マサヒロ・イズミ, DDS, PhD##, ケンイチ・クリタ, DDS, PhD###, エイチロー・アリジ DDS, PhD+

要約:

目的: 下顎管variationの位置と配置は、埋伏第三大臼歯抜歯、デンタルインプラント処置、下顎枝矢状分割術などの下顎外科処置において重要である。本論文は日本人における3件の二分下顎管症例を、パノラマX線像とmulti-slice helical CT像によって報告する。

パノラマX線像では5面のうち2面が、二分下顎管を示唆していた。再構成CT像では、4面で二分下顎管に第二大臼歯遠心部に向かって短く狭いupper canalがあり、1面で第二大臼歯遠心部に向かって短く狭いlower canalがあることがわかった。

下顎管variationの位置と配置は下顎における外科処置において重要であることから、これらは再構成CT像によって慎重に観察するべきである。

キーワード: 下顎管、二分、コンピュータ断層法、デンタルインプラント

-
- * 愛知学院大学スクール・オブ・デンティストリー口腔上顎顔面放射線学部准教授;愛知学院大学歯科病院口腔インプラントクリニック長
 - ** 愛知学院大学スクール・オブ・デンティストリー口腔上顎顔面放射線学部パートタイム講師
 - *** 愛知学院大学スクール・オブ・デンティストリー口腔上顎顔面放射線学部パートタイム講師
 - **** 愛知学院大学スクール・オブ・デンティストリー口腔上顎顔面放射線学部講師
 - # 愛知学院大学スクール・オブ・デンティストリー口腔上顎顔面放射線学部助教授
 - ## 愛知学院大学スクール・オブ・デンティストリー口腔上顎顔面放射線学部准教授
 - ### 愛知学院大学スクール・オブ・デンティストリー第一口腔上顎顔面外科学部長・教授
 - + 愛知学院大学スクール・オブ・デンティストリー口腔上顎顔面放射線学部長・教授

問い合わせ先: Munetaka Naitoh, DDS, PhD, Dept. of Oral and Maxillofacial Radiology, School of Dentistry, Aichi-Gakuin University, 2-11 Suemori-Dori, Chikusa-Ku, Nagoya 464-8651, Japan

日本人的下頷管分叉

作者：Munetaka Naitoh, DDS, PhD*、Yuichiro Hiraiwa, DDS**、Hidetoshi Aimiya, DDS***、Masakazu Gotoh, DDS****、Yoshiko Arijji, DDS, PhD#、Masahiro Izumi, DDS, PhD##、Kennichi Kurita, DDS, PhD### 和 Eiichiro Arijji, DDS, PhD+

摘要：下頷管變形的的位置和結構對和下頷有關的外科手術很重要，例如拔出裝填結實的第三白齒、牙科植體治療及雙側下頷支矢狀骨劈開術(SSRO)。我們使用環口放射線攝影術及多層螺旋電腦斷層攝影影像，記述3位下頷管分叉的日本患者。

環口放射線攝影顯示，5個部位中有2個下頷管分叉。在重組的電腦斷層影像中則發現，第二白齒末梢部分的4個部位下頷管分叉有短而窄的管，第二白齒末梢部分的一個部位有窄而低的管。

由於下頷管分叉變形的的位置和結構對和下頷有關的外科手術很重要，因此應該使用重組的電腦斷層影像仔細觀察。

關鍵字：下頷管、分叉、電腦斷層技術、牙科植體

* 愛知學院大學牙醫學院口腔與上頷放射學系副教授、愛知學院大學牙科醫院口腔移植診所主任

** 愛知學院大學牙醫學院口腔與上頷放射學系兼任講師

*** 愛知學院大學牙醫學院口腔與上頷放射學系兼任講師

**** 愛知學院大學牙醫學院口腔與上頷放射學系講師

愛知學院大學牙醫學院口腔與上頷放射學系助理教授

愛知學院大學牙醫學院口腔與上頷放射學系副教授

愛知學院大學牙醫學院第一口腔與上頷外科醫學學系系主任與教授

+ 愛知學院大學牙醫學院口腔與上頷放射學系系主任暨教授

通訊方式： Munetaka Naitoh, DDS, PhD, Dept. of Oral and Maxillofacial Radiology, School of Dentistry, Aichi-Gakuin University, 2-11, Suemori-Dori, Chikusa-Ku, Nagoya 464-8651, Japan

일본인의 분기 하악관

저자 : 나이토 무네타카, 치과의사(doctor of dental surgery), 치의학 박사,* 히라이와 요이치로, 치과의사,** 아이미야 히데토시, 치과의사,*** 고토 마사카즈, 치과의사,**** 아리지 요시코, 치과의사, 치의학 박사,# 이즈미 마사히로, 치과의사, 치의학 박사,## 쿠리타 켄이치, 치과의사, 치의학 박사### , 아리지 에이치로, 치과의사, 치의학 박사+

초록 : 하악관 변이의 위치와 형상은 매복 제3대구치의 적출, 치아 이식 치료 및 시상 분할 절골술과 같은, 하악골에 관련된 외과적 절차에 있어 중요하다. 우리는 파노라마 방사선 촬영과 다절편 나선식 CT 영상을 사용하여 분기 하악관을 가진 일본인 환자 3명에 관한 조사 결과를 보고한다.

파노라마 방사선 촬영의 경우에는, 5개 측면 사진 중 2개에서 분기 하악관이 발견되었다. 재구성 CT 영상의 경우에는, 4개 측면 영상에서는 분기 하악관이 제2대구치의 원위부를 향해 위쪽에 짧고 좁은 관을 가지고 있었고 1개 측면 영상에서는 분기 하악관이 제2대구치의 원위부를 향해 아래쪽에 짧고 좁은 관을 가지고 있었다.

하악관 변이의 위치와 형상은 하악골에 관련된 외과적 절차에 있어 중요하므로, 재구성 CT 영상을 사용하여 하악관 변이의 위치와 형상을 주의 깊게 관찰하여야 한다.

핵심 용어 : 하악관, 분기, 전산화 단층촬영, 치아 이식

- * 아이치가쿠인 대학교, 치과 대학, 구강악안면 방사선학과, 조교수; 아이치가쿠인 대학교, 치과 병원, 구강 이식과 과장
- ** 아이치가쿠인 대학교, 치과 대학, 구강악안면 방사선학과,시간 강사
- *** 아이치가쿠인 대학교, 치과 대학, 구강악안면 방사선학과,시간 강사
- **** 아이치가쿠인 대학교, 치과 대학, 구강악안면 방사선학과, 강사
- # 아이치가쿠인 대학교, 치과 대학, 구강악안면 방사선학과,조교수
- ## 아이치가쿠인 대학교, 치과 대학, 구강악안면 방사선학과, 부교수
- ### 아이치가쿠인 대학교, 치과 대학, 제1 구강악안면 외과학과, 교수 및 학과장
- + 아이치가쿠인 대학교, 치과 대학, 구강악안면 방사선학과, 교수 및 학과장

교신 저자: 나이토 무네타카, 치과의사,치의학 박사, 일본 나고야 464-8651 치쿠사쿠, 수에모리가 2-11, 아치-카쿠인 대학교 치과대학 구강 및 악골안면 방사선과